

QAL-FARABI KAZAKH NATIONAL UNIVERSITY
Medicine and Health Care Faculty
Higher School of Medicine
Department of Fundamental Medicine

Final exam program of
OMiF1214 Morphology and physiology of human body (8 credits)
Spring semester, academic year 2022-2023

Topics for the final exam

1. The Functions of Muscles, Muscle Attachments. Functional Groups of Muscles, Innervation and Blood Supply, Muscle Names and Learning Strategy.
2. The Nerve-Muscle Relationship. Behavior of Skeletal Muscle Fibers
3. Muscle tissue: smooth and striated skeletal muscle tissue. Nerve tissue. General features of Nerve tissue.
4. Behavior of the whole Muscle. Muscle Metabolism
5. Muscles of the head and neck
6. Muscles of the Anterior Abdominal Wall; Muscles of the Pelvic Floor; Muscles of the Back. Muscles of Respiration. Muscles Acting on the Hip and Femur, Muscles Acting on the Knee and Leg. Muscles Acting on the Foot, Intrinsic Muscles of the Foot
7. Muscles Acting on the Shoulder and Arm; Muscles Acting on the Forearm, the Wrist and Hand
8. Hemopoiesis. General features of Hematopoiesis. Blood. Formed elements: Erythrocytes, leukocytes, platelets
9. Introduction, Blood Types. Erythrocytes. Leukocytes.
10. Platelets and Hemostasis, The Control of Bleeding. Interpretation of blood test, coagulogram. Changes in blood system parameters.
11. Cardiovascular system. General features of the CVS. Blood vessels. Arteries and veins. Microcirculation stream. Arterioles. Capillaries. Venules
12. Overview of the Cardiovascular System. Gross Anatomy of the heart
13. Electrical and Contractile Activity of the Heart. ECG
14. Cardiac Muscle and the Cardiac Conduction System. Blood flow, heart sounds and cardiac cycle
15. Cardiac Output. General Anatomy of the Blood Vessels
16. Cardiovascular system. Cardiac Muscle muscle tissue. Heart. Layers of the Heart Wall.
17. Blood pressure, resistance and flow
18. Capillary Exchange. Regulation of blood pressure and flow
19. Venous Return and Circulatory Shock. Special Circulatory Routes. Anatomy of the Pulmonary Circuit
20. Systemic Vessels of the Axial Region
21. Lymphoid system. General features of the Lymphoid system. Thymus. Lymph Nodes. Spleen
22. The lymphatic and immune system.
23. Biophysics of the nervous system Electrophysiology of neuronal synapses. Biophysics of the neural integration of the nervous system
24. Histology of the supporting cells of the nerve tissue (neuroglia). Histology of the Nervous System Peripheral Nervous System. Ganglia. Spinal cord.

25. Anatomy of the Systemic Vessels of the Appendicular Region
26. Overview of the Nervous System. Properties of Neurons. Supportive Cells (Neuroglia). Synapses. Neural Integration. Spinal cord. Somatic reflexes.
27. Central nervous system. Brain. Cortex. Cerebellum. Overview of the meninges, ventricles, cerebrospinal fluid and blood supply
28. Spinal Nerves
29. Overview of the meninges, ventricles, cerebrospinal fluid and blood supply. Midbrain. Hindbrain. Forebrain.
30. Integrative functions of the brain
31. Cranial Nerves I.Cranial Nerves II.

Learning outcomes

Students on the final written and test exam must demonstrate in their responses the ability to:

- describe and identify the structural and organizational structure of internal organs, localize and describe, correctly using the appropriate terminology, on models, drugs and medical imaging materials, the typical structure of internal organs and systems of human organs (musculoskeletal system and skin, respiratory, circulatory systems) in the normal way, taking into account age, gender and individual characteristics;
- understand the functional organization of the human body at the cellular, systemic and organ level, the physiological processes of excitable tissues;
- recognize and identify micro-products; describe, correctly using the appropriate terminology, the microscopic structure of human organs, taking into account age, gender and individual characteristics;
- describe, using appropriate terminology, the stages of human development and explain the main processes and mechanisms of normal morphogenesis;
- explain the relationship of structure and function at the level of tissue, organs and organ systems, and the main physiological mechanisms for maintaining homeostasis, vital activity of the body and their features, taking into account age, gender and individual differences;\
- integrate knowledge about the structure of the musculoskeletal system, skin, respiratory and circulatory systems at the systemic, organ and tissue levels and their phylogenetic development to understand anatomical and physiological features in different periods of normal development;

An approximate typology of tasks for the exam

To pass the exam in writing

| № | Lesson topics | Exam question |
|---|---|--|
| 1 | Muscle system: - <i>The Functions of Muscles, Muscle Attachments. Functional Groups of Muscles, Innervation and Blood Supply, Muscle Names and Learning</i> | <i>describe five functions of muscle tissue; relate the muscle bundles to the shape and relative strength of the muscles; explain the disadvantages associated with the names of their attachments; distinguish between internal and external muscles; describe how the muscles work in groups to help, resist, and mitigate each other's actions. describe in general terms the nerve and blood supply to the skeletal muscles; list and define five characteristics of muscle contraction;</i> |

| | | |
|---|--|--|
| | <p><i>Strategy</i></p> <ul style="list-style-type: none"> - <i>The Nerve-Muscle Relationship. Behavior of Skeletal Muscle Fibers</i> - <i>Muscle tissue: smooth and striated skeletal muscle tissue. Nerve tissue. General features of Nerve tissue.</i> - <i>Behavior of the whole Muscle. Muscle Metabolism</i> - <i>Muscles of the head and neck</i> - <i>Muscles of the Anterior Abdominal Wall; Muscles of the Pelvic Floor; Muscles of the Back. Muscles of Respiration. Muscles Acting on the Hip and Femur, Muscles Acting on the Knee and Leg. Muscles Acting on the Foot, Intrinsic Muscles of the Foot</i> - <i>Muscles Acting on the Shoulder and Arm; Muscles Acting on the Forearm, the Wrist and Hand</i> | <p><i>describe the structure is transversely striated muscle;</i></p> <p><i>describe the model of sliding threads;</i></p> <p><i>determine the mechanical properties of bone tissue;</i></p> <p><i>determine strains of the muscle;</i></p> <p><i>determine the effective elastic modulus;</i></p> <p><i>determine the cross section of the tendon.</i></p> <p><i>list the three major muscle types and compare their structure, function, location</i></p> <p><i>define the structure and functions of the Skeletal Muscle.</i></p> <p><i>define the relationships among muscle fascicles, muscle fibers, myofibrils, myofilaments.</i></p> <p><i>recognize Skeletal muscle in micrographs, conclude the functions of muscle tissue based on their histological feature.</i></p> <p><i>identify components of the sarcomere on image.</i></p> <p><i>Describe the stages of muscle twitching;</i></p> <p><i>explain how successive muscle contractions can lead to stronger muscle contractions;</i></p> <p><i>difference between isometric and isotonic, concentric and eccentric contraction</i></p> <p><i>Explain how the skeletal muscle meets its energy needs during rest and exercise;</i></p> <p><i>discuss why additional oxygen is needed even after the exercise is over;</i></p> <p><i>explain the cause of muscle fatigue and soreness;</i></p> <p><i>discuss the impact of resistance and endurance exercises on your muscles,</i></p> <p><i>discuss the factors that affect muscle strength;</i></p> <p><i>distinguish two physiological types of muscle fibers and explain their functional role</i></p> <p><i>Describe the physiological properties that all types of muscles have;</i></p> <p><i>name and determine the location of the muscles that produce facial expressions</i></p> <p><i>name and determine the location of the muscles used for chewing and swallowing;</i></p> <p><i>name and locate the muscles of the neck by which the head moves,</i></p> <p><i>Determine the action of these muscles.</i></p> <p><i>Name and determine the location of the abdominal wall, back and pelvic floor muscles;</i></p> <p><i>determine the action of these muscles</i></p> <p><i>Explain how the breathing muscles affect air flow and abdominal pressure;</i></p> <p><i>Name and locate the muscles that act on the hip, knee joints, on the ankle and toes;</i></p> <p><i>correlate the actions of these muscles with the movements of the joints,</i></p> <p><i>describe the the action of these muscles</i></p> <p><i>Name and determine the location of the muscles that affect the pectoral girdle, shoulder, elbow, wrist, and arm,</i></p> <p><i>relate the actions of these muscles to the joints;</i></p> |
| 2 | <p>Circulatory System: Blood</p> <p>- <i>Hemopoiesis. General</i></p> | <p><i>describe the structural and functional characteristics of a stem cell.</i></p> <p><i>compare mature circulating blood cells and hematopoietic stem cells.</i></p> |

| | | |
|-----------------|---|--|
| | <p><i>features of Hematopoiesis. Blood. Formed elements: Erythrocytes, leukocytes, platelets</i></p> <p><i>- Introduction, Blood Types. Erythrocytes. Leukocytes.</i></p> <p><i>- Platelets and Hemostasis, The Control of Bleeding. Interpretation of blood test, coagulogram. Changes in blood system parameters.</i></p> | <p><i>define the sites and the phases of intrauterine hematopoiesis.</i></p> <p><i>define blood cells life span and site of postnatal hematopoiesis.</i></p> <p><i>recognize differences in the blood cells produced during each stage of postnatal hematopoiesis.</i></p> <p><i>describe general features of bone marrow.</i></p> <p><i>conclude the functions of blood cells based on their histological features</i></p> <p><i>describe the functions and main components of the circulatory system;</i></p> <p><i>describe the components and physical properties of blood;</i></p> <p><i>describe the composition of blood plasma; explain the value of blood viscosity and osmolarity;</i></p> <p><i>describe in general terms how blood is produced;</i></p> <p><i>explain what determines the ABO and Rh of human blood and how this is related to compatibility with blood transfusions;</i></p> <p><i>describe the consequences of incompatibility of the blood group between the mother and the fetus.</i></p> <p><i>Describe the structure and function of red blood cells;</i></p> <p><i>describe the structure and function of hemoglobin.</i></p> <p><i>determine clinical measurements of the number of red blood cells and hemoglobin; describe the life history of red blood cells;</i></p> <p><i>name and describe the types, causes and consequences of excessive and insufficient number of red blood cells</i></p> <p><i>explain the function of white blood cells in General and the individual role of each type of white blood cell;</i></p> <p><i>describe the appearance and relative prevalence of each type of white blood cell;</i></p> <p><i>describe the formation and life history of white blood cells;</i></p> <p><i>discuss the types, causes, and consequences of excessive and insufficient white blood cell counts</i></p> <p><i>describe the mechanisms for controlling bleeding in the body;</i></p> <p><i>list the functions of platelets;</i></p> <p><i>describe the two reaction pathways that cause blood clots to form,</i></p> <p><i>explain what happens to blood clots when they are no longer needed;</i></p> <p><i>explain what keeps the blood from clotting in the absence of injury,</i></p> <p><i>describe blood clotting disorders</i></p> <p><i>Explain the stages of platelet formation</i></p> <p><i>interpret the changes in blood system parameters</i></p> |
| <p>3</p> | <p>Circulatory System: Heart</p> <p><i>- Overview of the Cardiovascular System.</i></p> <p><i>Gross Anatomy of the heart</i></p> <p><i>- Electrical and Contractile Activity of the Heart.</i></p> | <p><i>identify and distinguish the pulmonary contour and the systemic contour;</i></p> <p><i>describe the general location, size, and shape of the heart;</i></p> <p><i>describe the pericardial sac that covers the heart.</i></p> <p><i>describe the three layers of the heart wall; identify the four chambers of the heart and correlate them with its internal and surface anatomy;</i></p> <p><i>identify the four valves of the heart;</i></p> |

| | | |
|-----------------|--|--|
| | <p><i>Electrocardiogram</i></p> <ul style="list-style-type: none"> - <i>Cardiac Muscle and the Cardiac Conduction System.</i> <i>Blood flow, heart sounds and cardiac cycle</i> - <i>Cardiac Output.</i> | <p><i>trace the blood flow through the four chambers and valves of the heart and adjacent blood vessels;</i></p> <p><i>describe the arteries that feed the myocardium and the veins that deplete it</i></p> <p><i>determine the mechanisms ECG registration;</i></p> <p><i>define an electric dipole;</i></p> <p><i>explain Einthoven's theory;</i></p> <p><i>explain the main provisions of the theory of Einthoven;</i></p> <p><i>explain the occurrence of ECG waves;</i></p> <p><i>determine the position of the electrical axis of the heart according to the results of the ECG;</i></p> <p><i>calculate heart rate and give a conclusion. describe the unique structural and metabolic characteristics of cardiac muscle;</i></p> <p><i>explain the nature and functional significance of the intercellular junctions between cardiac muscle cells;</i></p> <p><i>describe the heart's pacemaker and internal electrical conduction system;</i></p> <p><i>describe the nerve supply to the heart and explain its role.</i></p> <p><i>explain why blood pressure is expressed in millimeters of mercury;</i></p> <p><i>describe how changes in blood pressure operate the heart valves;</i></p> <p><i>explain what causes the sounds of the heartbeat;</i></p> <p><i>describe in detail one complete cycle of heart contraction and relaxation;</i></p> <p><i>relate the events of the cardiac cycle to the volume of blood entering and leaving the heart</i></p> <p><i>Define cardiac output and explain its importance;</i></p> <p><i>determine the factors that affect cardiac output</i></p> <p><i>discuss the nerve and chemical factors that change heart rate, stroke volume, and cardiac output.</i></p> <p><i>Explain how the right and left ventricles achieve balanced functioning;</i></p> <p><i>describe some of the effects of exercise on heart output</i></p> |
| <p>4</p> | <p>Circulatory System: Vessels</p> <ul style="list-style-type: none"> - <i>Cardiovascular system.</i> <i>General features of the CVS.</i> <i>Blood vessels. Arteries and veins. Microcirculation stream. Arterioles.</i> <i>Capillaries. Venules.</i> - <i>General Anatomy of the Blood Vessels</i> - <i>Cardiovascular system.</i> <i>Cardiac Muscle muscle tissue. Heart. Layers of the Heart Wall.</i> - <i>Blood pressure, resistance</i> | <p><i>name the 3 tunics that make up the walls of cardiovascular system components.</i></p> <p><i>describe the tissue type in each tunic in the wall of blood vessels.</i></p> <p><i>recognize the blood vessel types in a micrograph and identify their structural components.</i></p> <p><i>conclude the functions of blood vessels based on their histological feature, explain the role in conduction of blood and distribution of nutrients.</i></p> <p><i>recognize the artery types in a micrograph and identify their structural components of their wall, describe function of each layer.</i></p> <p><i>recognize the veins types in a micrograph and identify their structural components of their wall, describe function of each layer</i></p> <p><i>describe the structure of a blood vessel;</i></p> <p><i>describe the types of arteries, capillaries, and veins;</i></p> <p><i>trace the general route usually taken by the blood from the heart and back again;</i></p> <p><i>describe variations on this route.</i></p> <p><i>recognize the microcirculatory blood vessel types in a micrograph and identify their structural</i></p> |

| | | |
|---|---|---|
| | <p><i>and flow</i></p> <ul style="list-style-type: none"> - <i>Capillary Exchange. Regulation of blood pressure and flow.</i> - <i>Venous Return and Circulatory Shock. Special Circulatory Routes. Anatomy of the Pulmonary Circuit.</i> - <i>Systemic Vessels of the Axial Region</i> - <i>Anatomy of the Systemic Vessels of the Appendicular Region</i> - <i>Anatomy of the Systemic Vessels of the Appendicular Region.</i> | <p><i>components.</i></p> <p><i>recognize the arterioles, venules types in a micrograph and identify their structural components of their wall, describe function of each layer in micrographs.</i></p> <p><i>identify blood capillaries types in micrographs and compare them in terms of their features.</i></p> <p><i>define the blood speeds in different parts of the system, viscosity values, blood pressure on the walls of the vessel;</i></p> <p><i>describe the mechanism of the pulse wave and its propagation velocity, volumetric blood flow velocity;</i></p> <p><i>define conditions for the transition of the laminar flow to a turbulent;</i></p> <p><i>describe physical meaning of the Reynolds number;</i></p> <p><i>calculate the pressure, flow and viscosity of liquids using hydrodynamic laws and formulas.</i></p> <p><i>describe how materials get from the blood into the surrounding tissues;</i></p> <p><i>describe and calculate the forces that enable capillaries to give off and reabsorb fluid;</i></p> <p><i>describe the causes and effects of edema</i></p> <p><i>describe local, neural, and hormonal influences on the blood pressure</i></p> <p><i>Explain how the blood in the veins returns to the heart;</i></p> <p><i>discuss the importance of physical activity for venous return;</i></p> <p><i>discuss several causes of circulatory shock;</i></p> <p><i>name and describe the stages of shock</i></p> <p><i>explain how the brain maintains stable perfusion;</i></p> <p><i>discuss the causes and effects of strokes and transient ischemic attacks;</i></p> <p><i>explain the mechanisms that increase muscular perfusion during exercise; and</i></p> <p><i>contrast the blood pressure of the pulmonary circuit with that of the systemic circuit, explain why the difference is important in pulmonary function.</i></p> <p><i>trace the route of blood through the pulmonary circuit</i></p> <p><i>identify the principal systemic arteries and veins of the axial region;</i></p> <p><i>trace the flow of blood from the heart to any major organ of the axial region and back to the heart.</i></p> <p><i>identify the principal systemic arteries and veins of the limbs;</i></p> <p><i>trace the flow of blood from the heart to any region of the upper or lower limb and back to the heart.</i></p> <p><i>identify the principal systemic arteries and veins of the limbs;</i></p> <p><i>trace the flow of blood from the heart to any region of the upper or lower limb and back to the heart.</i></p> |
| 5 | <p>The Lymphoid system:</p> <ul style="list-style-type: none"> - <i>Lymphoid system. General features of the Lymphoid system. Thymus. Lymphoid system. Lymph Nodes. Spleen.</i> - <i>The lymphatic and immune</i> | <p><i>define the organs of the lymphoid system, distinguish between central and peripheral lymphoid organs.</i></p> <p><i>identify the organs of the lymphoid system, their components in micrographs.</i></p> <p><i>define main structural features of the lymphoid system organs.</i></p> <p><i>identify the thymus in micrographs, distinguish cortex and medulla, Hassall's corpuscle.</i></p> <p><i>describe the blood – thymus barrier in terms of its structural correlates and its function</i></p> <p><i>define and name the peripheral lymphoid organs.</i></p> <p><i>identify the peripheral lymphoid organs, their components in micrographs.</i></p> |

| | | |
|----------|--|---|
| | <p>system.</p> | <p><i>define main structural features of the peripheral lymphoid organs. identify the spleen in micrographs, distinguish white and red pulp. identify the lymph nodes in micrographs, distinguish cortex and medulla list the functions of the lymphatic system; explain how lymph forms and returns to the bloodstream; name the major cells of the lymphatic system and state their functions; name and describe the types of lymphatic tissue; describe the structure and function of the red bone marrow, thymus, lymph nodes, tonsils, and spleen.</i></p> |
| <p>6</p> | <p>The Nervous system: - <i>Biophysics of the nervous system Electrophysiology of neuronal synapses. Biophysics of the neural integration of the nervous system</i> - <i>Histology of the supporting cells of the nerve tissue (neuroglia). Histology of the Nervous System Peripheral Nervous System. Ganglia. Spinal cord.</i> - <i>- Central nervous system. Brain. Cortex. Cerebellum.</i> - <i>Overview of the meninges, ventricles, cerebrospinal fluid and blood supply.</i> - <i>Overview of the Nervous System. Properties of Neurons. Synapses. Neural Integration. Spinal cord. Somatic reflexes.</i> - <i>Spinal Nerves</i> - <i>Overview of the meninges, ventricles, cerebrospinal fluid and blood supply.</i></p> | <p><i>list the conditions for the emergence of resting potentials and actions on the membrane; define Nernst formula and Goldman-Hodgkin-Katz equation; determine of action potential; action potential phases; distribution of action potential along myelin and non-myelin nerve fibers; describe the mechanisms of the methods for registering biopotential as EEG, ECG, EMG. apply the appropriate formulas to calculate the value of the resting biopotential and action. name supporting cells of the nerve tissue compare supporting cells of the nerve tissue in terms of their features identify supporting cells in micrographs conclude the functions of neuroglial cells based on their histological features. compare myelinated and unmyelinated nerve fibers in terms of their features investigate the organs of the nervous system in the specimens according to key features of structure. identify and classify the peripheral and central organs of the nervous system. recognize the spinal ganglion in the specimens on the basis of key morphological features. determine the general structure of the peripheral nerve. identify the spinal cord and its horns in the specimen. Describe the functional significance of different nuclei. identify the layers of the cerebellar cortex. recognize the cerebellum in the specimens and slides. explain the functional peculiarities of cerebellar cortex on the basis of cellular content and relationship with other organs of the nervous system. recognise the cerebral cortex. recognise the cerebral cortex. identify the layers of the cerebral cortex. interpret the cytoarchitecture of the cerebral cortex. explain the differences between sensory and motor cortex. describe the agranular and granular types of cerebral cortex. describe the blood – brain barrier in terms of its structural correlates and its function describe the overall function of the nervous system;</i></p> |

| | |
|--|---|
| <p><i>Midbrain. Hindbrain. Forebrain.</i></p> <ul style="list-style-type: none"> - <i>Integrative functions of the brain</i> - <i>Cranial Nerves I</i> - <i>Cranial Nerves II</i> | <p><i>describe its major anatomical and functional subdivisions. describe three functional properties found in all neurons; define the three most basic functional categories of neurons; identify the parts of a neuron; explain how neurons transport materials between the cell body and tips of the axon. explain how messages are transmitted from one neuron to another; give examples of neurotransmitters and neuromodulators and describe their actions; explain how stimulation of a postsynaptic cell is stopped. explain how a neuron “decides” whether or not to generate action potentials; explain how the nervous system translates complex information into a simple code; explain how neurons work together in groups to process information and produce effective output; describe how memory works at the cellular and molecular levels. state the three principal functions of the spinal cord; describe its gross and microscopic structure; trace the pathways followed by nerve signals traveling up and down the spinal cord define reflex and explain how reflexes differ from other motor actions; describe the general components of a typical reflex arc; explain how the basic types of somatic reflexes function. describe the anatomy of nerves and ganglia in general; describe the attachments of a spinal nerve to the spinal cord; trace the branches of a spinal nerve distal to its attachments; name the five plexuses of spinal nerves and describe their general anatomy; name major nerves that arise from each plexus; explain the relationship of dermatomes to the spinal nerves. describe the major subdivisions and anatomical landmarks of the brain; describe the locations of its gray and white matter; describe the embryonic development of the CNS and relate this to adult brain anatomy describe the meninges of the brain; describe the fluid-filled chambers within the brain; discuss the production, circulation, and function of the cerebrospinal fluid that fills these chambers; explain the significance of the brain barrier system. list the components of the hindbrain and midbrain and their functions; describe the location and functions of the reticular formation. name the three major components of the diencephalon and describe their locations and functions; identify the five lobes of the cerebrum and their functions; describe the three types of tracts in the cerebral white matter; describe the distinctive cell types and histological arrangement of the cerebral cortex; describe the location and functions of the basal nuclei and limbic system.</i></p> |
|--|---|

| | | |
|--|--|--|
| | | <p><i>list the types of brain waves and discuss their relationship to mental states;</i></p> <p><i>b. describe the stages of sleep, their relationship to the brain waves, and the neural mechanisms of sleep;</i></p> <p><i>identify the brain regions concerned with consciousness and thought, memory, emotion, sensation, motor control, and language;</i></p> <p><i>discuss the functional differences between the right and left cerebral hemispheres.</i></p> <p><i>list cranial nerves by name and number;</i></p> <p><i>identify where each cranial nerve originates and terminates;</i></p> <p><i>state the functions of each cranial nerve.</i></p> <p><i>list cranial nerves by name and number;</i></p> <p><i>identify where each cranial nerve originates and terminates;</i></p> <p><i>state the functions of each cranial nerve.</i></p> |
|--|--|--|

The list of anatomical structures

| Muscular system | | |
|-------------------------------------|--|--------------------------|
| <i>Muscles of the Head and Neck</i> | | |
| m. frontalis | m. orbicularis oculi | m. digastricus |
| m. occipitalis | m. levator palpebrae superioris | m. geniohyoideus |
| m. corrugator supercilii | m. genioglossus | m. mylohyoideus |
| m. nasalis | m. hyoglossus | m. stylohyoideus |
| m. orbicularis oris | m. styloglossus | m. omohyoideus |
| m. levator labii superioris | m. palatoglossus | m. semispinalis capitis |
| m. levator anguli oris | m. temporalis | m. semispinalis cervicis |
| m. zygomaticus major | masseter | m. trapezius |
| m. zygomaticus minor | m. pterygoideus lateralis | m. splenius capitis |
| m. risorius | m. pterygoideus medialis | m. splenius cervicis |
| m. depressor anguli oris | m. sternothyroideus | Platysma |
| m. depressor labii inferioris | m. constrictor pharyngi superior, medius, inferior | m. sternohyoideus |
| m. mentalis | m. sternocleidomastoideus | m. thyrohyoideus |
| m. buccinator | m. scalenus anterior, medius, and posterior | |

| <i>Muscles of the Trunk</i> | | |
|---|--------------------------------------|--------------------------------------|
| diaphragma | m. semispinalis thoracis | m. transversus abdominis |
| mm. intercostales externi | m. quadratus lumborum | m. rectus abdominis |
| mm. intercostales interni | m. multifidus | m. erector spinae |
| mm. intercostales intimi | m. ischiocavernosus | m. compressor urethrae |
| m. obliquus externus abdominis | m. bulbospongiosus | m. sphincter ani externus |
| m. obliquus internus abdominis | m. transversus perinei superficialis | m. levator ani |
| <i>Muscles acting on the Upper Limb</i> | | |
| m. pectoralis minor | m. flexor digitorum superficialis | m. triceps brachii |
| m. serratus anterior | m. palmaris longus | m. brachioradialis |
| m. trapezius | m. flexor digitorum profundus | m. anconeus |
| m. levator scapulae | m. flexor pollicis longus | m. pronator quadratus |
| m. rhomboideus minor | m. extensor carpi radialis longus | m. pronator teres |
| m. rhomboideus major | m. extensor carpi radialis brevis | m. supinator |
| m. pectoralis major | m. extensor digitorum | m. flexor carpi radialis |
| m. latissimus dorsi | m. extensor digiti minimi | m. flexor carpi ulnaris |
| m. teres major | m. extensor carpi ulnaris | m. opponens pollicis |
| m. coracobrachialis | m. abductor pollicis longus | m. abductor digiti minimi |
| m. supraspinatus | m. extensor pollicis brevis | m. flexor digiti minimi brevis |
| m. infraspinatus | m. extensor pollicis longus | m. opponens digiti minimi |
| m. teres minor | m. extensor indicis | mm. interossei dorsales |
| m. subscapularis | m. adductor pollicis | m. three palmar interosseous muscles |
| m. brachialis | m. abductor pollicis brevis | mm. lumbricales |
| m. biceps brachii | m. flexor pollicis brevis | |
| <i>Acting acting on the Lower Limb</i> | | |
| m. iliacus | m. semimembranosus | m. quadriceps femoris |
| m. psoas major | m. popliteus | m. rectus femoris |
| m. tensor fasciae latae | m. fibularis tertius (peroneus) | m. vastus lateralis |

| | | |
|---------------------------------------|--|--|
| m. gluteus maximus | m. extensor digitorum longus | m. vastus medialis |
| m. gluteus medius, m. gluteus minimus | m. extensor hallucis longus | m. vastus intermedius |
| m. gemellus superior | m. tibialis anterior | m. sartorius |
| m. gemellus inferior | m. gastrocnemius | m. biceps femoris |
| m. obturator externus | m. soleus | m. semitendinosus |
| m. obturator internus | m. flexor digitorum longus | m. abductor hallucis |
| m. piriformis | m. flexor hallucis longus | m. quadratus plantae |
| m. quadratus femoris | m. tibialis posterior | mm. lumbricales |
| m. adductor brevis | m. fibularis brevis | m. flexor digiti minimi brevis |
| m. adductor longus | m. fibularis longus | m. flexor hallucis brevis |
| m. adductor magnus | m. extensor digitorum brevis | m. adductor hallucis |
| m. gracilis | m. flexor digitorum brevis | mm. interossei dorsales |
| m. pectineus | m. abductor digiti minimi | mm. interossei plantares |
| Cardiovascular System | | |
| <i>Heart</i> | | |
| pericardium fibrosum | anulus fibrosus | myocardium |
| cavitas pericardiaca | sulcus coronarius | atrium sinistrum et atrium dextrum |
| epicardium | sulcus interventricularis anterior et posterior | mm. pectinati |
| basis cordis | valva atrioventricularis dextra (valva tricuspidalis) et sinistra (valva mitralis) | auricula sinistra et auricula dextra |
| apex cordis | mm. papillare | ventriculus sinister et ventriculus dexter |
| vena cava superior | valva aortae | septum interventriculare |
| vena cava inferior | valva trunci pulmonalis | r. marginalis dexter |
| arcus aortae | chordae tendineae | r. interventricularis posterior |
| truncus pulmonalis | a. coronaria sinistra | v. cardiaca magna |
| aa. pulmonales | r. interventricularis anterior | v. interventricularis posterior |
| aorta | r. circumflexus | vv. marginales |
| pericardium serosum | r. marginalis sinister | sinus coronarius |

| | | |
|---------------------------------|-------------------------|-----------------------------|
| endocardium | a. coronaria dextra | |
| <i>Vessels</i> | | |
| sinus caroticus | a. ilealis | a. subscapularis |
| a. lobaris superior | a. ileocolica | v. subclavia |
| aa. lobaris inferior | a. colica media | v. brachiocephalica |
| aorta ascendens | a. sigmoidea | superior vena cava |
| truncus brachiocephalicus | a. rectalis superior | v. azygos |
| a. carotica communis | a. vaginalis | v. ascending lumbar |
| a. subclavia sinistra | a. obturatoria | v. hemiazygos |
| aorta descendens | a. pudenda interna | a. phrenica inferior |
| a. vertebralis | a. vesicalis superior | aa. suprarenales superiores |
| truncus thyrocervicalis | a. uterina | truncus coeliacus |
| truncus costocervicalis | a. iliolumbalis | mesenterica superior |
| a. carotica externa | a. glutea superior | aa. renales |
| a. thyroidea superior | vena cava inferior | aa. testiculares |
| a. lingualis | v. iliaca communis | aa. lumbares |
| a. occipitalis | vv. lumbares | a. ovarica |
| a. maxillaris | vv. ovaricae | a. sacralis mediana |
| a. temporalis superficialis | vv. testiculares | a. iliaca communis |
| a. ophthalmica | vv. renales | a. hepatica communis |
| a. cerebri anterior | v. suprarenalis | a. gastroduodenalis |
| a. cerebri posterior | vv. hepaticae | a. hepatica propria |
| a. basilaris | vv. lumbares ascendens | a. lienalis |
| a. cerebelli posterior inferior | v. mesenterica inferior | a. gastro-omentalis dextra |
| a. cerebelli anterior inferior | v. lienalis | v. axillaris |
| a. communicans anterior | v. hepatica propria | v. subclavia |
| aa. communicans posterior | v. cystica | a. iliaca externa |
| sinus sagittalis superior | a. subclavia | a. femoralis |

| | | |
|-------------------------------|--------------------------|-----------------------------------|
| sinus sagittalis inferior | a. axillaris | a. femoralis profunda |
| sinus transversus | a. circumflexa humeri | a. femoralis circumflexa |
| sinus cavernosus | a. brachialis | a. poplitea |
| v. jugularis interna | a. collateralis radialis | a. tibialis anterior |
| v. facialis | a. collateralis ulnaris | a. dorsalis pedis |
| v. jugularis externa | a. radialis | a. arcuata |
| v. vertebralis | a. ulnaris | a. tibialis posterior |
| hiatus aorticus | a. interossea | a. plantaris lateralis |
| rr. bronchiales | arcus palmaris | arcus plantaris profundus |
| rr. esophageales | rete venosum dorsale | a. fibularis |
| aa. mediastinales | v. cephalica | arcus venosus dorsalis |
| aa. intercostales posteriores | v. basilica | v. saphena magna et parva |
| aa. subcostales | v. mediana cubiti | arcus plantaris venosus profundus |
| a. phrenica superior | v. mediana antebrachii | vv. fibulares |
| a. thoracica interna | arcus venosus palmaris | v. poplitea |
| a. pericardiophrenica | vv. radial | v. femoralis |
| aa. intercostales anteriores | vv. ulnar | v. iliaca communis |
| truncus thoracoacromialis | vv. brachial | |
| Nervous system | | |
| medulla oblongata; | tegmentum | putamen |
| pons | aqueductus cerebri | capsula interna |
| cerebellum; | corpora quadrigemina | pedunculus cerebri |
| ventriculus quartus | colliculus superior | gyrus cinguli |
| ventriculus lateralis | colliculus inferior | corpus mammillare |
| ventriculus tertius | chiasma opticum | hyppocampus |
| pyramis | vermis cerebelli | thalamus |
| oliva | folia | plexus choroideus |
| lobus temporalis | cauda equina | commissura anterior |

| | | |
|----------------------------|-----------------------------------|----------------------|
| lobus frontalis | medulla spinalis | glandula pinealis |
| lobus occipitalis | radix anterior et posterior | n. facialis |
| hypothalamus | conus medullaris | n. glossopharyngeus |
| corpus callosum | dura mater | n. vagus |
| sulcus centralis | pia mater | n. olfactorius |
| gyrus postcentralis | arachnoidea mater | n. trochlearis |
| gyrus precentralis | cornu posterius | n. oculomotorius |
| hypophysis | cornu anterius | n. trigeminus |
| sulcus parieto-occipitalis | ramus anterior et posterior | n. abducens |
| cortex cerebri | ganglion sensorium nervi spinalis | n. hypoglossus |
| amygdala | n. opticus | n. accessorius |
| nucleus caudatus | n. vestibulocochlearis | n. phrenicus |
| n. medianus | n. auricularis major | n. axillaris |
| n. radialis | n. ulnaris | n. occipitalis minor |
| n. femoralis | n. obturatorius | n. ischiadicus |

List of histological slides:

1. Striated skeletal muscular tissue of tongue. Iron hematoxylin. x 630.
2. Neurofibrils in multipolar neurons of the anterior horns of the spinal cord. x 400.
3. Granules of basophilic substance in the cytoplasm of motor neurons of the spinal cord. x200, x400.
4. Human blood smear. Romanovsky-Giemsa. x 400.
5. Human blood smear. Eosinophil. Romanovsy-Giemsa. x 1000.
6. Human blood smear. Neutrophils. Romanovsy-Giemsa. x 1000.
7. Human blood smear. Basophil. Romanovsy-Giemsa. x 1000.
8. Human blood smear. Monocyte. Romanovsy-Giemsa. x 1000.
9. Section of red bone marrow. Hematoxylin – eosin. x 400.
10. Myocardium. Iron hematoxylin. x 400.

11. Muscular artery. Hematoxylin – eosin. x 400.
12. Muscular vein. Hematoxylin – eosin. x 200.
13. Elastic artery. Orcein. x400
14. Thymus. Hematoxylin – eosin. x 100.
15. Lymph node. Hematoxylin – eosin. x 100.
16. Spleen. Hematoxylin – eosin. x 100.
17. Spinal ganglion. Hematoxylin – eosin. x 400.
18. Transverse section of myelinated nerve. Osmium impregnation. x200
19. Transverse section of spinal cord. Silver impregnation. x40
20. Cerebellum. Silver impregnation. x 200, x400
21. Cerebral cortex. Silver impregnation. x 200

Example of physiology assignment:

- 1) Describe the importance of the viscosity and osmolarity of blood, what accounts for each, and the pathological effects of abnormal viscosity or osmolarity. Describe excesses and deficiencies in RBC count and the forms, causes, and pathological consequences of each
- 2) Describe mechanisms of presynaptic facilitation and inhibition, and how communication between two neurons can be strengthened or weakened by a third neuron employing one of these mechanisms. Explain the cellular basis of memory; what memory consists of in terms of neural pathways, and how it relates to synaptic plasticity and potentiation

Examples of questions on medical terminology

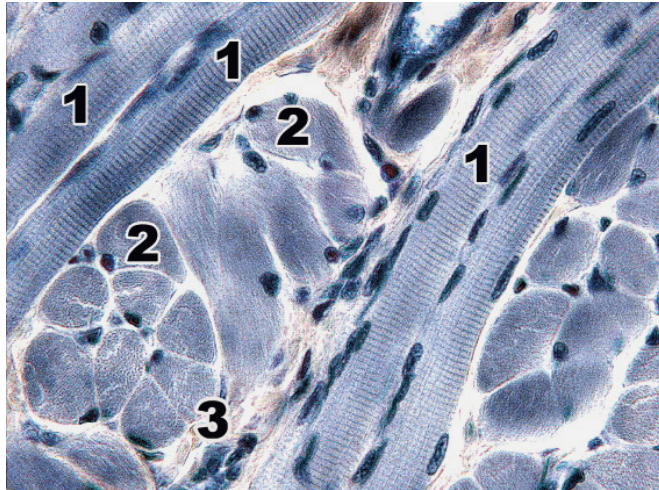
Write the term denoting the following:

1. Narrowing of the aorta -
2. Destruction of a blood clot -
3. Weakness of muscle -
4. Without nourishment -

Sample assignment for histology

Striated skeletal muscular tissue of tongue. Iron hematoxylin. x 630.

Identify the structures of the skeletal muscular tissue indicated by the numbers. Describe the structure of the muscle fiber. Explain the features of the regeneration of striated muscle tissue.



Example of an OSPE stations

5 station – the muscles of the lower limbs

Identify the muscles of the lower extremities listed below on the model. Fill in the empty fields in the table (number, action)

| № | Name of the muscle | action |
|---|----------------------------|--------|
| | M. flexor hallucis longus | |
| | M.gastrocnemius | |
| | M. gluteus medius | |
| | M. gracilis | |
| | M. vastus lateralis | |
| | M. flexor digitorum brevis | |
| | M. lumbrical | |
| | M. quadratus femoris | |

Station 8 - HISTOLOGY

Identify the tissue that you can now see under the magnification of the microscope. Then find a microphotograph of this tissue and describe it using the form below.

Description of microphotography

| | |
|--|--|
| Name of the tissue under the microscope | |
| Individual structural elements (Research objects) | <ol style="list-style-type: none"> 1. 2. 3. 4. 5. |
| Structural features of this tissue | |
| Function | |

HISTOLOGY ASSESSMENT CRITERIA

| Mark | Criteria | Points |
|-------------|--|-----------------|
| Excellent | <p>Assessment of theoretical competence All key aspects are included and presented logically; high accuracy (relevance, no redundancy) and constant attention to the issue; excellent integration of theoretical issues; providing relevant examples; in-depth analysis and theoretical substantiation of this problem, all key aspects are identified and interpreted; fluency in histological terminology. The work is done within the specified time;</p> <p>Assessment of practical competence A student absolutely correctly and fully described the histological specimen: a student can distinguish the organ and its staining; properly identified major tissue type from which organ is</p> | 100 - 90 |

| | | |
|------------------------|--|---------|
| | <p>composed and cellular organization of this structure and listed its function; when describing the histological slide a student demonstrated a competence and logically correct presents his thoughts, correctly used histological terminology; The work is done within the specified time;</p> | |
| Good | <p>Assessment of theoretical competence all key aspects are included and presented logically; constant focus on the issue with satisfactory accuracy, relevance; satisfactory integration of theoretical issues; lack of examples; satisfactory analysis and theoretical substantiation of this problem, most of the key aspects are identified and interpreted; correct use of histological terminology; The work is done within the specified time;</p> <p>Assessment of practical competence A student make some mistakes when describing the histological slide: partially and uncertainly called the organ and the slide which described; didn't fully describe and didn't identify major tissue type from which organ is composed and cellular organization of this structure and its function; correct use of histological terminology; the work is done within the specified time;</p> | 89 - 70 |
| Satisfactory | <p>Assessment of theoretical competence Most key aspects included; satisfactory focus on the issue - some errors and / or noticeable redundancy; theoretical problems presented without noticeable integration; Providing bad examples or no examples; Some analysis and theoretical substantiation of this problem, most of the key aspects are identified and interpreted; correct use of histological terminology. the work is not done within the specified time;</p> <p>Assessment of practical competence A student make some mistakes during description the histological slide: couldn't completely name the structures of the organ and its tissues; gets confused when describe the cellular composition of organ's tissues; name their functions; correct use of histological terminology the work is not done within the specified time;</p> | 69 - 50 |
| Unsatisfactory (FX) | <p>Assessment of theoretical competence Most of the key aspects are missing; lack of attention to the issue - irrelevance and significant redundancy; some theoretical problems presented without integration and understanding; absence or irrelevant examples; some analysis and theoretical substantiation of this problem, most of the key aspects are missing; problems in the use of histological terminology. the work is not done within the specified time.</p> | 49 - 25 |

| | | |
|---------------------------------------|--|----------------------|
| | <p>Assessment of practical competence A student could not identify the histological specimen and didn't distinguish the organ, couldn't identify major tissue type from which organ is composed and cellular organization of this structure and its function, the work is not done within the specified time.</p> | |
| <p>Unsatisfactory (F)</p> | <p>Assessment of theoretical competence most or all key aspects are missing; no concentration on the issue, a lot of irrelevant information; significant gaps in theoretical issues, or their superficial consideration; lack of examples or irrelevant examples; no analysis and no theoretical substantiation of the given problem, most of the key aspects are missing; problems in the use of histological terminology the work is not done within the specified time. A student refused to answer; cheated, used copy paste</p> <p>Assessment of practical competence A student could not identify the histological specimen and didn't distinguish the organ, couldn't identify any tissue type from which organ is composed and cellular organization of this structure and its function. the work is not done within the specified time. A student refused to answer; cheated, used copy paste</p> | <p>24 - 0</p> |

Response quality scale (written / oral response)

| Mark | Criteria | Scale, points |
|-------------|--|----------------------|
| Excellent | <ol style="list-style-type: none"> 1. all key aspects are included and presented logically; 2. high accuracy (relevance, without redundancy) and constant attention to the issue; 3. excellent integration of theoretical questions; 4. providing relevant examples; 5. in-depth analysis and theoretical justification of the problem (if applicable), all key aspects identified and interpreted; 6. fluency in professional terminology | 90 - 100 |
| Good | <ol style="list-style-type: none"> 1. all key aspects are included and presented logically; 2. constant focus on the issue with satisfactory accuracy, relevance, and / or some redundancy; 3. satisfactory integration of theoretical questions; 4. the lack of examples; 5. satisfactory analysis and theoretical justification of the problem (if applicable), most of the key | 70 - 89 |

| | | |
|---------------------|---|---------|
| | aspects identified and interpreted; 6. correct use of professional terminology | |
| Satisfactory | 1. most of the key aspects are included; 2. satisfactory focus on the question - some errors and / or noticeable redundancy; 3. theoretical problems presented without noticeable integration; 4. Providing failed examples or no examples; 5. some analysis and theoretical justification of this problem (if applicable), most of the key aspects are defined and interpreted; 6. correct use of professional terminology | 50 - 69 |
| Unsatisfactory (FX) | 1. most of the key aspects are omitted; 2. lack of attention to the issue-irrelevant and significant redundancy; 3. some theoretical problems presented without integration and understanding; 4. missing or outdated examples; 5. some analysis and theoretical justification of this problem (if applicable), most of the key aspects are omitted; 6. problems in using professional terminology | 25 - 49 |
| Unsatisfactory (F) | 1. most or all of the key aspects are omitted; 2. no focus on the question, not much related to the issue of information; 3. significant gaps in theoretical questions, or their superficial consideration; 4. the lack of examples or irrelevant examples; 5. there is no analysis and no theoretical justification for the given problem (if applicable), most of the key aspects are omitted; 6. problems in using professional terminology | 0-24 |

Grading system

| Rating by letter system | Digital equivalent of points | Percentage | Evaluation using the traditional system |
|-------------------------|------------------------------|------------|---|
| A | 4 | 95-100 | Excellent |
| A- | 3,67 | 90-94 | |
| B+ | 3,33 | 85-89 | |

Good

| | | | |
|-------------------|------|-------|---|
| B | 3 | 80-84 | |
| B- | 2,67 | 75-79 | |
| C+ | 2,33 | 70-74 | |
| C | 2 | 65-69 | Satisfactory |
| C- | 1,67 | 60-64 | |
| D+ | 1,33 | 55-59 | |
| D- | 1 | 50-54 | |
| FX | 0 | 25-49 | Unsatisfactory |
| F | 0 | 0-24 | |
| I (Incomplete) | - | - | «Discipline is not completed» (it is not taken into account when calculating the GPA) |

**WRITTEN EXAM:
TRADITIONAL - ANSWERS TO QUESTIONS.**

The process of taking a written exam by the student involves the automatic creation of an exam ticket for the student, to which you must form a written answer by direct handwriting.

Exam Technology Instructions

1. The duration of the exam is exactly 3 hours.
2. Written exams are administered according to the approved schedule.
3. Students may enter the auditorium where the written exam is administered only with an ID card (Passport or student ID card). The presence of persons not participating in the examination procedure is prohibited.
4. The proctor reconciles the identification document with the admission permission slip. A student who has a discipline clearance rating of less than 50% is not allowed to take the written exam.
5. The proctor (calls the names from the list and sits them down according to the list) starts them in the auditorium.
6. Late students are not allowed to take the exam.
7. Proctor gives each student an answer sheet (if necessary, the student may take an additional answer sheet) and gives the student the opportunity to choose a ticket for the discipline being passed (the text of the ticket should not be visible to the student).
8. Students present at the exam must sign the admission form.
9. The start and end times of the written exam are recorded on the blackboard.
10. During the written exam, students' questions on the content of the examination tickets are not considered.
11. If the student does not comply with the established requirements at the exam: uses crib notes, mobile and other devices, allows disciplinary violations, disturbs other students with their actions, the proctor has the right to remove student from the audience. In this case, an act of violation of the examination procedure is drawn up, the answer sheet is annulled by crossing out diagonally, the mark "Removed for violation" is made in

the admission sheet, "0" points will be given in the sheet.

12. It is allowed for a student to visit the restroom no more than 1 time per hour, lasting no more than 5 minutes. If frequent visits to the restroom are required (for example, due to health conditions), the student must undergo a medical examination, and the exam is counted as the student's absence from the exam.

13. At the end of the exam, the student must turn in his/her ticket and answer sheet.

Basic literature:

1. Saladin, Kenneth S: Anatomy & Physiology. The Unity of Form and Function, 9th Edition (2020, McGraw-Hill Education), ISBN-10 1260571297, 978-1260571295
2. Costanzo, Linda S.: BRS Physiology. Board Review Series.7 edition. -Wolters Kluwer Health, 2018.- 307p. - ISBN 1496367693, 9781496367693
3. Leslie P. Gartner: Color Atlas and Text of Histology. - 7th Edition. - Wolters Kluwer, 2017. ISBN 1496346734, 9781496346735
4. Russell K. Hobbie, Bradley J. Roth: Intermediate Physics for Medicine and Biology. - Springer, 2015. - ISBN 3319126822, 9783319126821
5. Andersson D, Medical Terminology: The Best and Most Effective Way to Memorize, Pronounce and Understand Medical Terms: Second Edition, ISBN-13 : 978-1519066626, 2016
6. Shoibekova, Alima Zhorabaevna. Latin and Fundamentals of Medical Terminology for Medical Students with Training English [Text] : educational man. / A. Zh. Shoibekova, 2016. - 163, [1] p.
7. Sembulingam, K. Essentials of Medical Physiology [Text] : [monogr.] / K. Sembulingam, P. Sembulingam ; Madha Medical College [et al.]. - 7th ed. - New Delhi ; London ; Philadelphia : Jaypee, 2016. - 1112 p. : il. - Ind.: p. 1069-1112. - ISBN 978-93-85999-11-6

Additional literature:

8. Standring, Susan: Gray's Anatomy: The Anatomical Basis of Clinical Practice. - 41 Elsevier Limited, 2016
9. Elaine N. Marieb, Lori A. Smith: Human Anatomy & Physiology Laboratory Manual, Main Version. - 11 edition. - Pearson Education,2015. - ISBN 9780133999143
10. Scanlon V. C, Essentials of Anatomy and Physiology 8th Edition, F.A. Davis Company, 2018
11. Victor P. Eroschenko, Atlas of Histology with Functional Correlations 13th Edition, LWW, 2017
12. William Bialek: Biophysics: Searching for Principles. -Princeton University Press, 2012. - ISBN 0691138915, 9780691138916
13. Ghosh, Byas Deb. Human Anatomy [Text] : For Students / B. D. Ghosh ; [Anatomical Society of India (West Bengal Chapter) et al.]. - 2nd ed. - New Delhi ; Panama City ; London : Jaypee, 2013. - 948 p. : il. - Ind.: p. 913-948. - ISBN 978-93-5025-942-9
14. Mazumdar, Sibani. Anatomy at a Glance [Text] : An Exam-Oriented Text / S. Mazumdar ; Calcutta National Medical College [et al.]. - 2nd ed. - New Delhi ; London ; Philadelphia : Jaypee, 2014. - 534 p. : il. - Ind.: p. 525-534. - ISBN 978-93-5152-355-0 : App.: p. 519-520. Glossary: p. 521-524.
15. Baktybayeva, Lyaila Kyrgyzbayevna. Base of Physiology [Text] : laboratory practicum / L. K. Baktybayeva, G. T. Zhamanbayeva, M. S. Kulbayeva ; Al-Farabi Kazakh National University. - Almaty : Qazaq University, 2017. - 146 p. : il. - Bibliogr.: p. 145. - ISBN 978-601-04-3138-6

Online resources:

1. <https://app.lecturio.com/#/>
2. <https://3d4medical.com/>

3. https://www.youtube.com/channel/UCc_I2c2bUtO0p4DVeo6-Kxg
4. <https://sites.google.com/a/umich.edu/bluelink/curricula/anatomy-403?authuser=0>
5. <https://histologyknmu.wixsite.com/info/gistologicheskie-sajty>
6. <http://www.histology-world.com/contents/contents.htm>
7. <http://www.histologyguide.com/slidebox/02-epithelium.html>
8. <https://histology.medicine.umich.edu/resources>
9. <https://web.duke.edu/histology/>
10. <http://virtualslides.med.umich.edu/Histology/view.apml?listview=1&>